FREE

Nursing Cheat Sheet Booklet

Your essential resource to ace nursing school



lecturio NURSING

www.lecturio.com/nursing

Table of Contents

4 About us

4 How to use this booklet

5 How to Get More Cheat Sheets

6 Cheat Sheets

6 Needle Gauges
7 Wound Documentation
8 Lung Sounds: Normal Findings
9 Normal Vital Sounds in Pediatrics by Age
10 Lung Sounds: Lung Auscultation Guide
11 How to Read an ECG
12 Head-to-Toe Assessment
13 Cranial Nerves: Chart & Mnemonic
14 SABA vs LABA Drugs
15 Heart Sounds: Normal and Abnormal

16 Wrap Up

16 Find Us on Social Media





About us

Lecturio is your all-in-one platform for excelling in nursing school and passing your exams.

As a nursing student, you are constantly juggling multiple subjects, complex medical terms, and intricate procedures. We have compiled 10 most popular nursing topics into a practical, easy-to-review booklet to help you streamline your study sessions and give you quick access to key information that will support your learning journey.

How to use this booklet

Flip through the pages to find the Cheat Sheets that cover critical nursing topics and use them as quick references during your study sessions to refresh your knowledge. Take note of the key points and incorporate them into your regular study sessions to retain the information better.

For deeper learning, **scan the QR codes** at the top of each Cheat Sheet to access selected Lecturio video lectures and expand your understanding.



Happy learning!

How to Get More Cheat Sheets

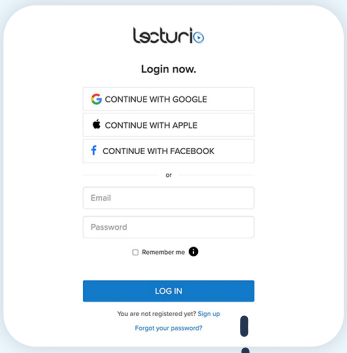

1 Create your Lecturio account

Head to **https://nursing.lecturio.com/** and sign up for a free account. It takes just a few minutes and will grant you access to even more resources.

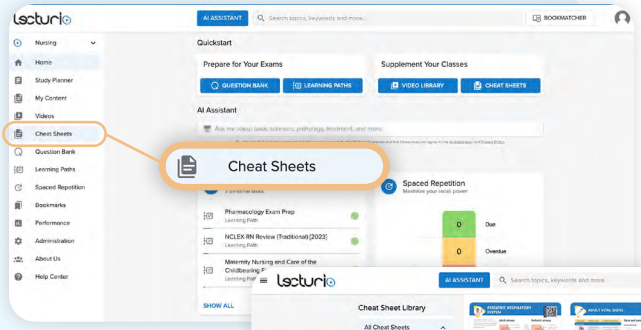

2 Explore our library

Once you've logged in, head to the "Cheat Sheets" section of your dashboard. There, you'll find our full collection of downloadable Cheat Sheets organized by subject.

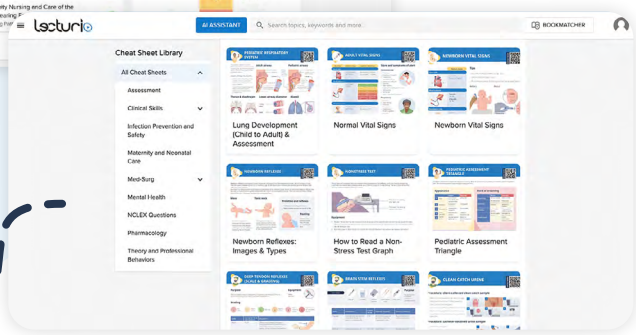

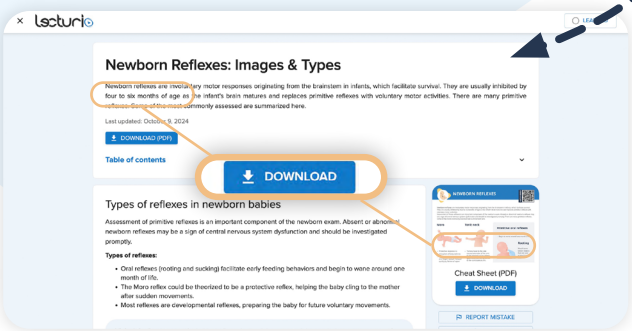

3 Download & study

Simply click on the Cheat Sheet you need, and download it straight to your device. You can print it out or keep it digitally to use anytime during your studies.

PRO TIP

Stay updated! With your account, you will be notified whenever we release new Cheat Sheets and other useful study tools.

DISCOUNT CODE: nursing20

Use the code to get **20% discount** on Basic and Premium Lecturio Nursing plans

Get my membership!

NEEDLE GAUGES

WATCH VIDEO!

The Three Parts of a Needle

1. **Hub:** fits onto the end of the syringe
2. **Shaft:** hollow needle opening or lumen
3. **Bevel:** slanted pointed tip

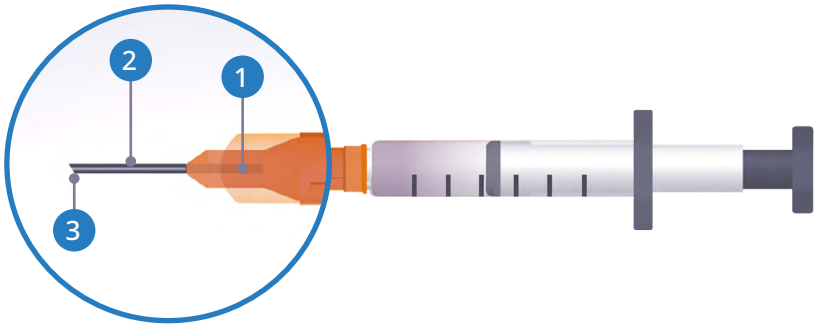

Needle Gauge Chart

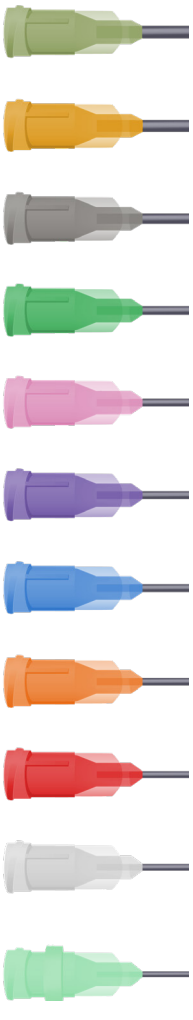

14 GAUGE. Color: olive
Outer diameter: 0.072 in (1.83 mm)

15 GAUGE. Color: amber
Outer diameter: 0.065 in (1.65 mm)

16 GAUGE. Color: gray
Outer diameter: 0.064 in (1.63 mm)

18 GAUGE. Color: green
Outer diameter: 0.050 in (1.27 mm)

20 GAUGE. Color: pink
Outer diameter: 0.036 in (0.91 mm)

21 GAUGE. Color: purple
Outer diameter: 0.033 in (0.83 mm)

22 GAUGE. Color: blue
Outer diameter: 0.027 in (0.70 mm)

23 GAUGE. Color: orange
Outer diameter: 0.025 in (0.63 mm)

25 GAUGE. Color: red
Outer diameter: 0.020 in (0.53 mm)

27 GAUGE. Color: white
Outer diameter: 0.016 in (0.42 mm)

Filter needle

CLINICAL TIP

Verify gauge and needle length before use!

Needle gauges represent the size of the needle. They are available in standard sizes, coded colors, and varying in length. The **LARGER** the gauge number, the **SMALLER** the needle shaft. A 22 gauge needle has a smaller shaft than a 14 gauge needle.

Needle gauge/size	Usage	Types of injections
21–22–23 gauge	Injection of large amounts of medication into muscular layer of the skin	Intramuscular
24–27 or 29 gauge	Administering medication and test agents (e.g., tuberculin test agents) into the dermal layer	Intradermal
27 or 25 gauge	Introducing medication just below dermal layer of skin (e.g., when administering insulin)	Subcutaneous
Filter needle (needle with small, glass filtering device)	Preparing medication from ampule	Administering medications withdrawn from a glass ampule

WOUND DOCUMENTATION

WATCH VIDEO!

SUPPLIES



Measuring tape



Sterile cotton tip applicator

Three areas of wound assessment and documentation

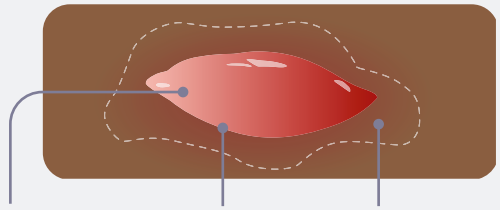

Assessment of wound bed

Location

"Wound on right medial thigh, distal to the femur."

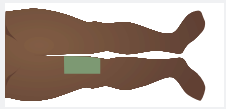

Type of wound

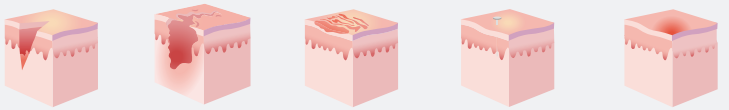

Incision | Laceration | Abrasion | Puncture | Pressure

Type of wound tissue



Granulation tissue | Slough | Necrotic

Wound measurements: Include length, width, depth.

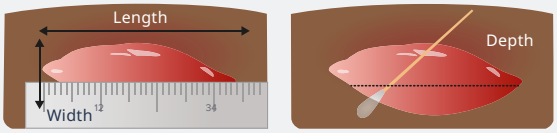

Exudate: Document amount of exudate, color, consistency, and odor.

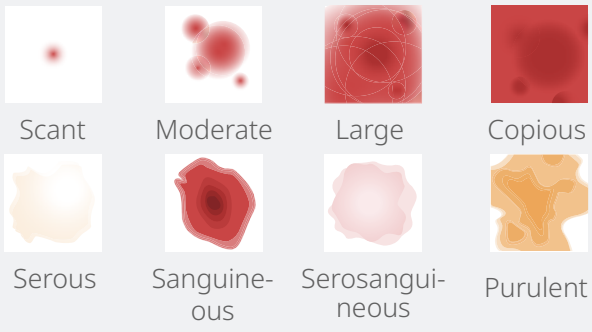

Consistency: thin, thick, tenacious

Odor: no odor, foul

Assessment of wound edge

Maceration



Softening of tissues by soaking in fluids

Tunneling (undermining)

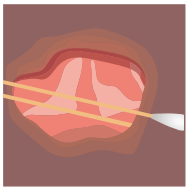

Erosion of tissue under wound edges, causes pocket beneath skin

Rolled edge



Edge rolls over itself, causing body to think wound has healed. Healing ceases prematurely.

Assessment of peri-wound skin

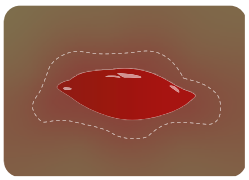

Assess for redness, warmth, edema, pain, skin breakdown.

Note any areas of maceration, excoriation, dry skin, hyperkeratosis, callus, eczema.

Signs of abnormal wound healing

- Increased pain or swelling
- Stiff movement in affected limb
- Pus or odorous exudate
- Tunneling
- Erythema of peri-wound skin
- Wound gaping open or not healing

NORMAL LUNG SOUNDS

WATCH VIDEO!

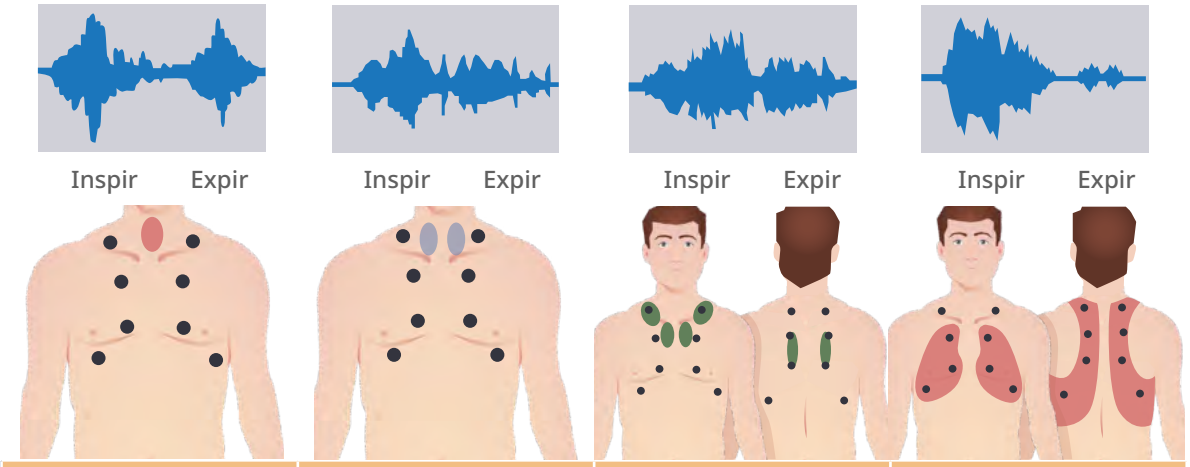

Lung sound	Tracheal	Bronchial	Bronchovesicular	Vesicular
Location best heard	Trachea	Large airways in the anterior chest near the second and third intercostal spaces	In the posterior chest between the scapulae and in the center of the anterior chest	Most lung spaces
Sounds like	Harsh, like air in a pipe	Loud and high in pitch	Softer than bronchial sounds with a tubular quality	Soft, blowing, or rustling sounds
Lung sound caused by	Normal breathing through the trachea	Normal breathing	Normal breathing	Normal breathing

NOTES



NORMAL VITAL SIGNS IN PEDIATRICS BY AGE

WATCH VIDEO!



Infant 0–12 months

	Normal Range
Heart Rate	100 – 180
Blood Pressure	72 – 104 / 37 – 56
Respirations	30 – 53



Toddler 1–2 years

	Normal Range
Heart Rate	90 – 140
Blood Pressure	86 – 106 / 42 – 63
Respirations	20 – 37



Preschooler 3–5 years

	Normal Range
Heart Rate	80 – 120
Blood Pressure	89 – 112 / 46 – 72
Respirations	20 – 28



School-age child 6–9 years

	Normal Range
Heart Rate	75 – 118
Blood Pressure	97 – 115 / 57 – 76
Respirations	18 – 25



Adolescent 10–15 years

	Normal Range
Heart Rate	60 – 100
Blood Pressure 10 – 12 years 13 – 15 years	102 – 120 / 61 – 80 110 – 131 / 64 – 83
Respirations	12 – 20

EXAM HINT

Pediatric respiratory distress is the leading cause of cardiac collapse.

CLINICAL TIP

- Check vital signs while patient is held by parents
- Keep babies warm and swaddled
- Check blood pressure last. If needed, leave blood pressure cuff on and return to check later when calm

PAY ATTENTION

Start CPR on a infant – 12 year old with a heart rate less than 60.

ABNORMAL LUNG SOUNDS

WATCH VIDEO!

Lung sound	Wheeze	Crackles (rales)	Rhonchi	Stridor	Pleural friction rub
Amplitude of lung sound	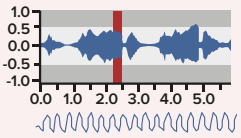	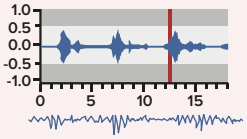	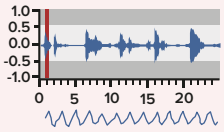	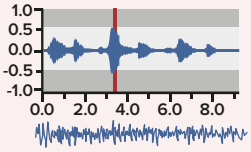	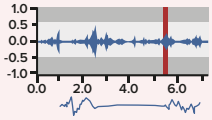
Location best heard	Most lung spaces	Commonly heard at the lung bases	Heard best over the large airways	• Trachea and upper airways • More commonly heard with inspiration, but may be heard during both inspiration and expiration	Most lung spaces
Sounds like	• High-pitched whistling sound • Commonly heard with expiration • May be heard with inspiration or throughout cycle depending on severity of inflammation and constriction	• Bubbling, popping, or clicking noises • Best heard during inhalation • May be described as moist, dry, fine, or coarse	Low-pitched rattling sounds that may sound like snoring, gurgling, or wheezing	High-pitched variable respiratory sound	Creaking, grating, rubbing
Lung sound caused by	Vibrations of constricted airway walls induced by a diminished airflow	Fluid in the smaller areas of the lungs such as alveoli	Blockage in the large airways caused by fluid, mucus, or other secretions in the lungs	• Rapid, turbulent flow of air through a narrowed or partially obstructed segment of the extrathoracic upper airway • Involved areas include the pharynx, epiglottis, larynx, and the extrathoracic trachea.	Inflammation causes roughing of the surfaces of the visceral and parietal pleura.

NOTES



BASIC ECG INTERPRETATION

WATCH VIDEO!

The electrocardiogram (ECG) is a tool for recording and interpreting cardiac activity through repeated cardiac cycles.

Anatomy of a normal cardiac cycle

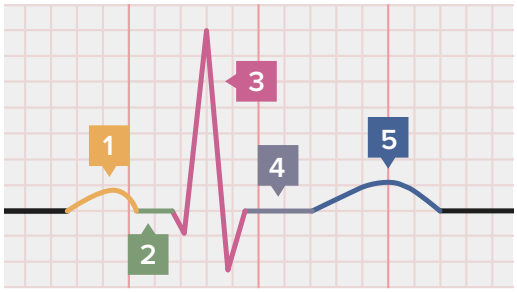

1. **P wave:** atrial depolarization/contraction
2. **PR interval:** electrical impulse passes through AV node, where pace of conduction is slowed, allowing the ventricles to fill before contracting
3. **QRS complex:** ventricular depolarization/contraction
4. **ST segment:** ventricles remain depolarized
5. **T wave:** ventricular repolarization/relaxation

Normal sinus rhythm (NSR)

NSR is the default, healthy cardiac rhythm. The electrical impulse originates from the sinoatrial (SA) node and the ECG strip will demonstrate the following characteristics:

P wave: present before each QRS complex
PR interval: 0.12–0.20 sec
QRS duration: 0.04–0.44 sec
T wave: present
Rate: 60–100 bpm, measured from R wave to R wave
Rhythm: regular

Common variations from NSR

Sinus bradycardia: All features of a normal cardiac rhythm are present, but rate is slower than 60 bpm.



Sinus tachycardia: All features of a normal cardiac rhythm are present, but rate is greater than 100 bpm. T wave may be "buried," or absent, at increased HR.



Interpreting the ECG strip

When a client is connected to the ECG monitor, the paper strip will emerge from the ECG machine at a rate of 25 mm per second. This rate and the system of large and small squares on the ECG strip allow measurement and interpretation of the client's cardiac activity.

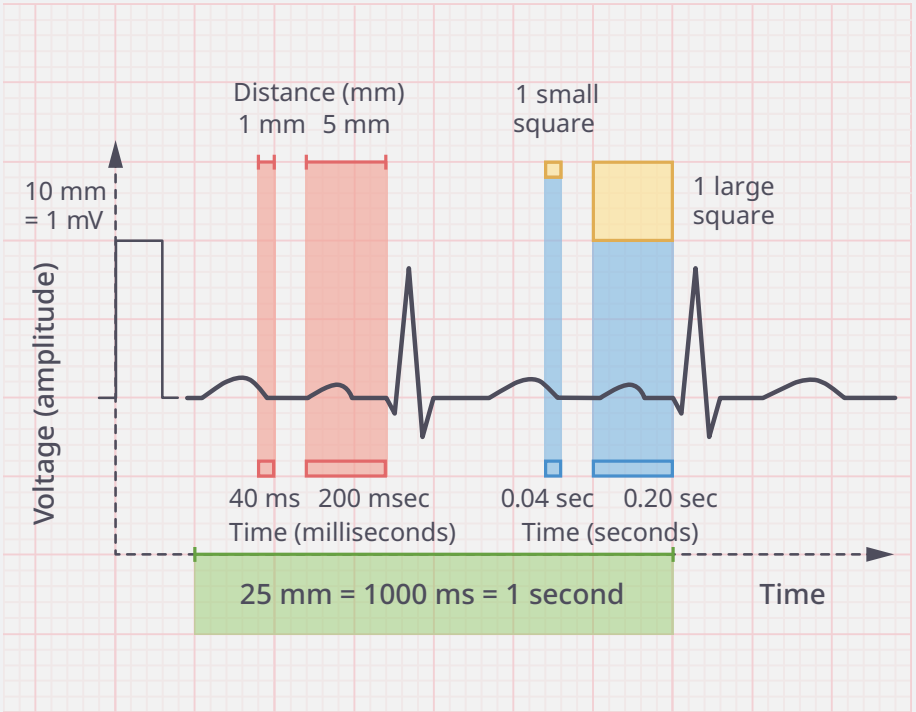

One small square = 40 ms or 0.04 sec **One large square** = 200 ms or 0.20 sec

The example above shows a PR interval (from the start of the P wave to the start of the QRS complex) of 0.20 sec, which is normal.

HEAD-TO-TOE ASSESSMENT

WATCH VIDEO!

Body systems

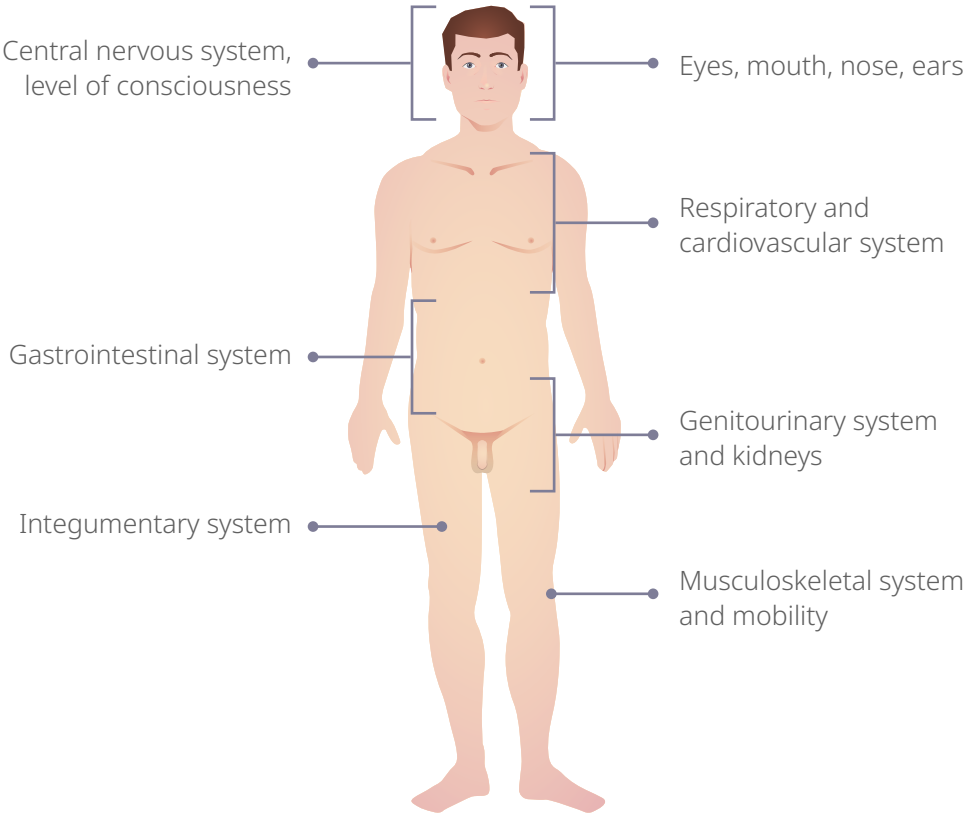

Assess any devices such as drains, tubes, and IV lines

NURSING NOTE

Organize your assessment!

1. Be systematic
2. Compare sides
3. Take notes

PAY ATTENTION

For an abdominal assessment you inspect, auscultate, percuss, then palpate.

4 Primary tools of assessment

1 Inspection

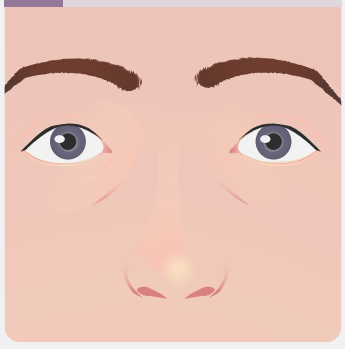

2 Palpation



3 Percussion

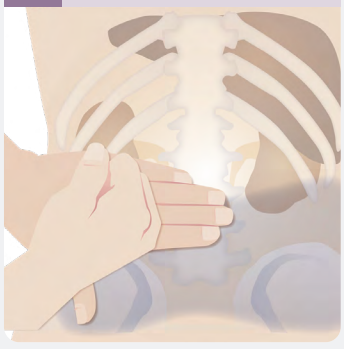

4 Auscultation

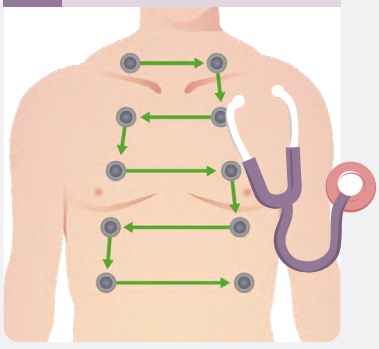

CRANIAL NERVES

WATCH VIDEO!

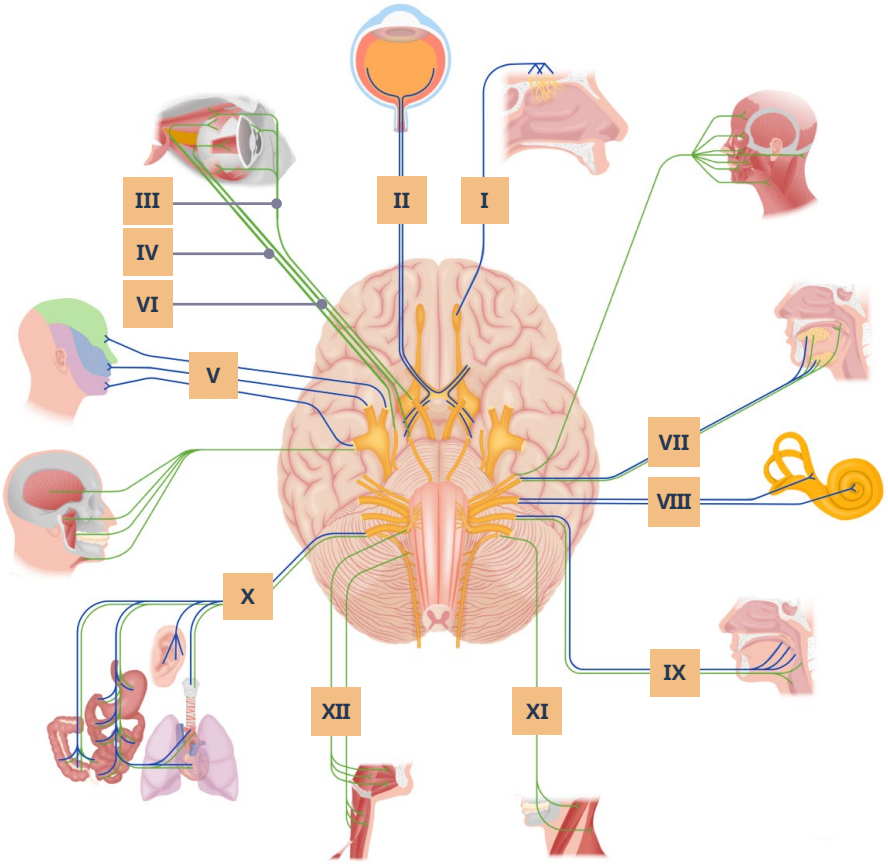

The **12 cranial nerves** as they exit from the brain and the primary sites of innervation

LEARNING TIP

Assess cranial nerves three, four, and six to see if the eyes do tricks.

EXAM HINT

Cranial nerves are named and numbered in Roman numerals according to their location, from the front to the back of the brain.

	Cranial nerve	Function	Mnemonic	Sensory, motor, or both
I	Olfactory	Smell	**O**nly	Some
II	Optic	Ability to see	**O**ne	Say
III	Oculomotor	Eye movement, pupillary constriction, accommodation, eyelid opening	**O**f	Marry
IV	Trochlear	Eye movement (up & down, back & forth)	**T**he	Money
V	Trigeminal	Facial sensation, taste & jaw movements	**T**wo	But
VI	Abducens	Abduction of eyes	**A**thletes	My
VII	Facial	Facial expression & taste	**F**elt	Brother
VIII	Vestibulocochlear	Sense of hearing & balance	**V**ery	Says
IX	Glossopharyngeal	Taste & swallow	**G**ood	Big
X	Vagus	Digestion & heart rate	**V**ictorious	Brains
XI	Accessory	Movement of head and shoulders	**A**nd	Matter
XII	Hypoglossal	Tongue movement	**H**ealthy.	More

COMPARISON OF SHORT-ACTING AND LONG-ACTING ASTHMA MEDICATIONS

WATCH VIDEO!

Inflammation & bronchoconstriction

Asthma is characterized by two airway alterations: inflammation and bronchoconstriction.

Asthma medications reverse or inhibit these alterations in order to open the airway and reduce asthma symptoms.

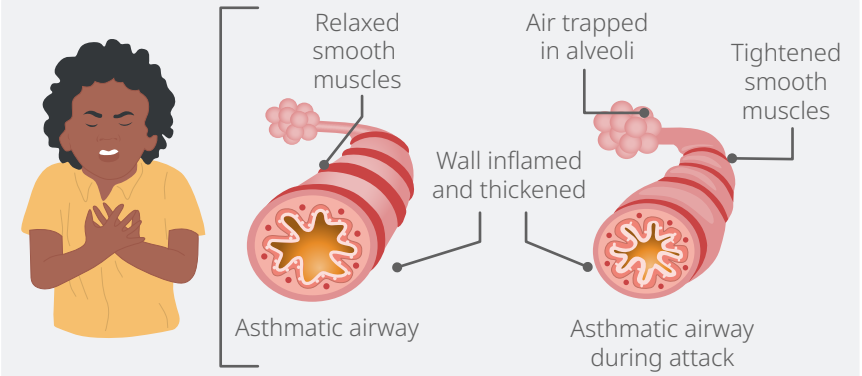

CLIENT EDUCATION

Rescue vs maintenance
Explain the action of each medication in the treatment plan, the difference between short- and long-acting medications, and when to use each.

Proper administration
Demonstrate use of the client's inhaled medication device, including spacer use if indicated. Verify understanding through teach-back method.

Signs of uncontrolled asthma
Adjustments to the treatment plan may be needed if symptoms are not controlled. Educate clients to report:

- More than two exacerbations per week
- Increased use of rescue inhaler
- Frequent nighttime awakening

	Rescue: for acute exacerbations	Maintenance: long-term therapy to reduce inflammation and prevent exacerbations				
Class	**Short-acting beta-agonists (SABAs)**	**Long-acting beta-agonists (LABAs)**	**Inhaled gluco-corticoids**	**Antileukotriene modifiers**	**Mast cell stabilizers**	**IgE antagonists**
Mechanism of action	Activate beta-2 receptors in lungs; rapid bronchodilaton	Activate beta-2 receptors in lungs; sustained smooth muscle relaxation	Suppress inflammatory response pathways	Block inflam-matory effects of leukotreines	Prevent mast cell breaking down	Inhibit IgE activation of mast cells
Onset/ duration of action	Quick onset of action, duration of action ~ 4 hours	Slower onset of action, longer duration ~ 12 hours	May take several days to weeks to note improvement	May take several weeks to note benefit	May take 2 days–2 weeks to note benefit	7–8 days from start of injec-tions to clinical benefit
Medication names	Albuterol Levalbuterol	Arformoterol Formoterol Indacaterol Salmeterol	Beclomethasone Budesonide Flunisolide Fluticasone	Montelukast Zafirlukast Zileuton	Cromolyn	Omalizumab
Route	Inhaled	Inhaled	Inhaled	Oral	Inhaled	Subcutaneous

HEART SOUNDS: NORMAL AND ABNORMAL

WATCH VIDEO!

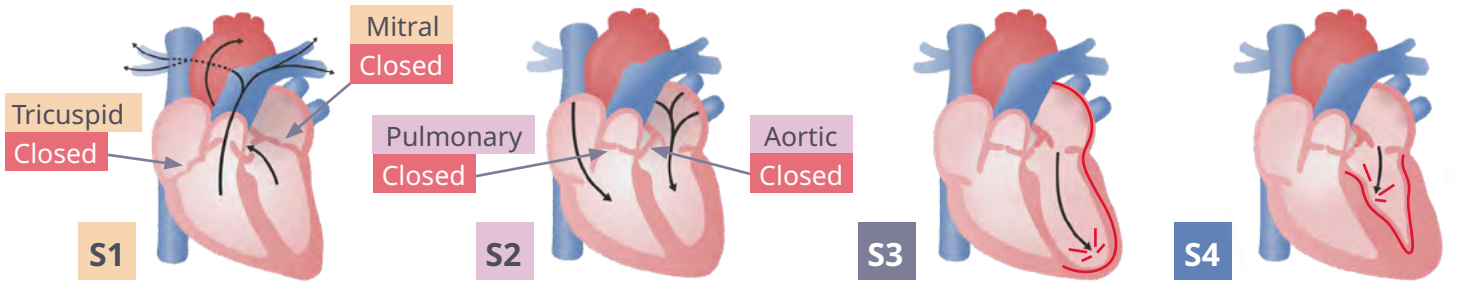

Normal heart sounds			
Heart sound	Cardiac cycle phase	Location best heard	Heart sound caused by
S1	Systolic	Cardiac apex	Mitral and tricuspid valves closing
S2	Diastolic	Right upper sternal border	Aortic and pulmonic valves closing
S3	Diastolic	Cardiac apex	Rapid filling of ventricles

Abnormal heart sounds			
Heart sound	Cardiac cycle phase	Location best heard	Heart sound caused by
S4	Diastolic	Cardiac apex	S4 occurs before S1
Systolic murmur	Systolic	Left upper sternal border	Occurs at or after S1 and ends before or at S2
Diastolic murmur	Diastolic	Left midclavicular area	The heart relaxing in between beats after S2 and before S1
Pericardial rub	Systolic and diastolic	Left sternal border	Parietal and visceral pericardial layers rubbing together
Ejection click	Systolic and diastolic	Varies	Maximal opening of the aortic or pulmonary valves

NOTES

Wrap Up

We understand the challenges of nursing school, and we hope these Cheat Sheets will make your study sessions a little easier. Whether you are preparing for exams, clinical rotations, or just want to brush up on key concepts, keep these Cheat Sheets close by. They are designed to reinforce your understanding and help you feel more confident on your journey.

Remember: you have got this! Nursing school can be demanding, but with the right tools and support, you can succeed. Keep these Cheat Sheets handy and check Lecturio Nursing for more study resources.

For additional resources, create your free account at https://nursing.lecturio.com/

Create your account

You can access an entire library of nursing study aids designed to support you throughout your academic journey. From concise video lectures, practice questions, NCLEX prep and much more.

Whether you need help with pharmacology, anatomy, or nursing theories, we've got you covered!

DISCOUNT CODE: nursing20

Use the code to get **20% discount** on Basic and Premium Lecturio Nursing plans

Get my membership!

Find Us on Social Media

lecturio_nursing
www.instagram.com/lecturio_nursing/

lecturio_nursing
www.tiktok.com/@lecturio_nursing

Lecturio Nursing
www.facebook.com/lecturio.nursing

Lecturio Nursing
www.youtube.com/@lecturionursing

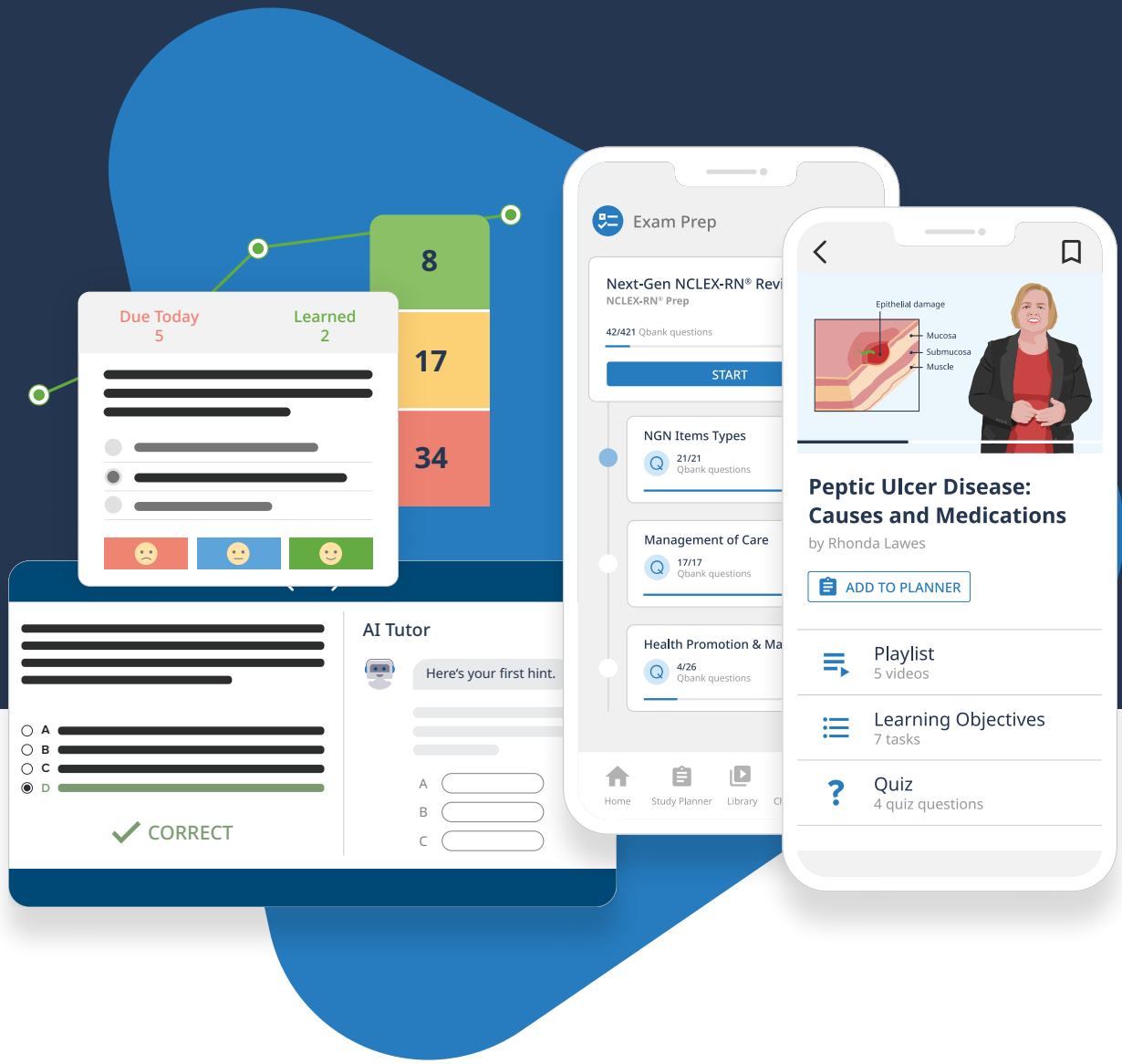

lecturio NURSING

www.lecturio.com/nursing